

CASE REPORT

Fulminant myopericarditis in an immunocompetent adult due to pandemic 2009 (H1N1) influenza A virus infection

ALI REZA DAVOUDI¹, ALI REZA MALEKI², AMIR REZA BEYKMOHAMMADI³ & ATEFE TAYEBI¹

From the ¹Department of Infectious Disease, Mazandaran University of Medical Sciences, North Iranian Research Centre for Infectious Disease, Sari, ²Student Research Committee, Faculty of Medicine, Golestan University of Medical Sciences, Gorgan, and ³Faculty of Medicine, Zahedan University of Medical Sciences, Zahedan, Iran

Abstract

Acute myopericarditis is a well-recognized but rare complication of numerous viral infections. Here we report a case of fulminant myopericarditis presenting with acute heart failure and a state of shock in a previously healthy young woman. H1N1 influenza A virus sequences were identified in throat and pericardial fluid, suggesting a viral source of the infection.

Keywords: *Pandemic 2009/H1N1, pericardial effusion, myocarditis*

Introduction

The 2009 (H1N1) influenza A virus was first reported from Mexico in April 2009 and rapidly spread throughout the world [1]. Cardiac involvement during seasonal influenza infection is a well-recognized condition that rarely presents with myopericarditis and pericardial effusion [2]. However, viral infection is one of the most prevalent aetiological factors of pericarditis, and the prevalence of cardiac involvement and myopericarditis caused by influenza infection is not yet known [3–5].

We present a case of fulminant myopericarditis with pericardial effusion in a previously healthy adult resulting from a novel 2009 (H1N1) influenza A infection. This was the second case of fulminant myopericarditis and pericardial effusion in a previously young healthy adult at our clinic during the current novel influenza A (H1N1) pandemic.

Case report

On 1 January 2011, a 30-y-old woman presented to a local general clinic with symptoms of an upper respiratory tract infection. She was suffering from fever and chills, myalgia, cough, nausea, and vomiting. She was

first seen by a general practitioner, who prescribed antipyretics and antibiotics. After 5 days she had made no improvement and finally presented to the emergency unit of Imam Khomeini Hospital in Sari with more severe symptoms and new onset epigastric pain. An electrocardiogram and an abdominal ultrasonogram taken at this time were normal. She only had an elevated white blood cell count of 16.5×10^9 cells/l. Thus she was discharged with an oral prescription and a diagnosis of a seasonal influenza.

On the morning of 6 January her general condition had worsened and she was admitted to the emergency unit of the Sari Heart Centre with respiratory distress and severe epigastric and chest pain, which radiated to the back. On physical examination she had a high fever at 39.5°C, was tachycardic at 124 beats/min, had tachypnoea of 32 breaths/min, normal jugular pulsation, and her blood pressure was 80/pulse mmHg (both arms), suggestive of shock. Lung and cardiac auscultation revealed no specific findings. In the routine blood sample analysis she had an elevated white blood cell count of 24.7×10^9 cells/l, and qualitative C-reactive protein assessment was positive (3+). The MB fraction of creatine phosphokinase (CPK-MB) level was elevated at 362 ng/ml (normal range CK-MB 0–3 ng/ml). The troponin

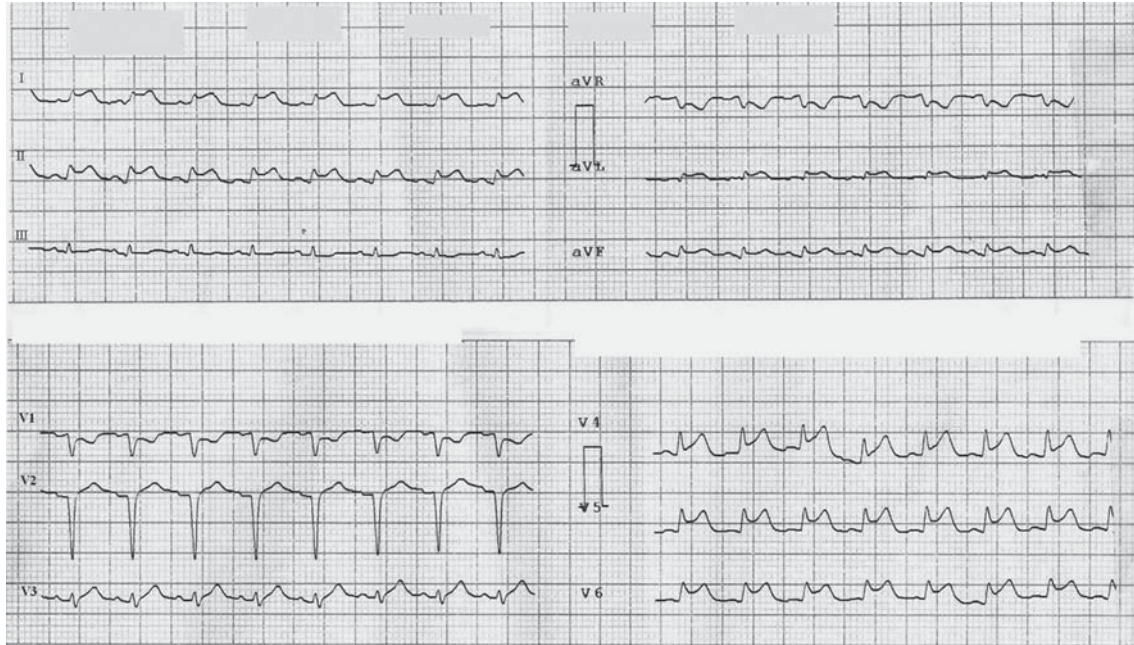

Figure 1. An electrocardiogram performed on admission to the Sari Heart Centre revealed diffuse ST-segment elevation and sinus tachycardia of 150 beats/min.

level was 4.13 ng/ml (normal range <0.4 ng/ml) and the lactate dehydrogenase level was 677 IU/l (normal adult range 0–250 IU/l). An electrocardiogram showed a sinus tachycardia with diffuse ST-segment elevation (Figure 1). Chest X-ray revealed an increased cardiothoracic ratio (cardiac enlargement) with bilateral clear lungs. An urgent bedside echocardiogram demonstrated severely compromised pump function (ejection fraction 15%), left ventricular enlargement, right ventricle and atrium diastolic collapse, and moderate to large pericardial effusion (Figure 2). A bedside abdominal ultrasonographic examination revealed a small amount of fluid in the Morison pouch and mild right side pleural effusion.

Treatment was started with oseltamivir (150 mg twice daily), ceftriaxone (1 g twice daily), vancomycin

(1 g twice daily; changed to 1 g daily after a rise in creatinine), and ranitidine (15 mg three times daily), and the patient was transferred to the coronary care unit (CCU) for further care and treatment. Before CCU admission a pericardiocentesis was performed and 150 ml of pericardial fluid was aspirated. The pericardial fluid contained 150 white blood cells/mm³ with 69% segmented neutrophils, 700 red blood cells/mm³, protein of 2.3 g/dl, albumin of 1.7 g/dl, sugar of 72 mg/dl, and lactate of 4000 U/l. Real-time polymerase chain reaction analysis of a nasopharyngeal swab and pericardial fluid was positive for the pandemic H1N1 2009 influenza virus. The patient was also examined for other common bacterial and viral respiratory agents (e.g. pneumococcus, Mycoplasma, etc.), and the results were all negative.

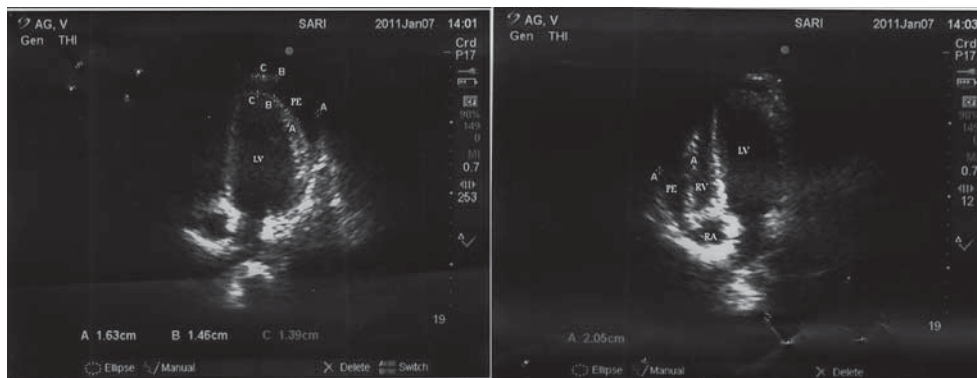


Figure 2. A bedside transthoracic echocardiogram shows left ventricular (LV) enlargement, right ventricle (RV) and right atrium (RA) diastolic collapse, and moderate to large pericardial effusion (PE) on both sides.

On CCU admission she had severe respiratory failure and her arterial O₂ saturation (SaO₂) was decreased at 83%; she was intubated and put on full mechanical ventilation for 24 h. A central venous line was inserted into the right subclavian vein for central venous pressure (CVP) monitoring. In the CCU the patient was isolated for 4 days and was started on furosemide (20 mg twice daily), captopril (6.25 mg twice daily), and spironolactone (12.5 mg daily). Following an improvement in her general condition the patient was transferred to the cardiology ward. The patient was discharged 4 days later with a normal electrocardiogram and in good condition.

Discussion

Acute myopericarditis has infectious and non-infectious causes. Bacterial agents such as Haemophilus influenzae type b should be considered as a source in countries where the vaccine is not used, such as Iran [2]. Viruses are the most prevalent infectious causes of myocarditis and pericarditis. Enteroviruses, especially group B coxsackieviruses, appear to be the major implicated agents [4].

There have already been several reports of H1N1 cardiac involvement in different age groups [3,5–8]. Most have reported various degrees of isolated myocarditis with or without cardiogenic shock. They have suggested that the novel H1N1 influenza A virus is more associated with severe cases of myocarditis than previously encountered influenza strains [3,4]. Our case involved a massive pericardial effusion that caused cardiac tamponade and acute heart failure in a young healthy woman. Simultaneously we found elevated cardiac enzymes that confirmed the myocardial involvement in this case. This is the second case of fulminant myopericarditis at our clinic, presenting 1 y after the first. Also, there has been a report of an 11-y-old girl in Italy who died of acute myopericarditis and cardiac tamponade due to a pandemic 2009 H1N1 influenza A virus infection [4].

As we saw in our case, cardiac involvement in influenza is usually reported to occur during the first week after the onset of influenza symptoms [4]. Acute left ventricular dysfunction and cardiogenic shock are the main features of fulminant myocarditis that may worsen by cardiac tamponade in the case of myopericarditis. The pathogenesis of myopericarditis is not clear. Two main described mechanisms of myocyte damage are direct viral invasion and a host immune-mediated pathology [2,9]; the former mechanism usually plays the main role in cases with early cardiac involvement.

The diagnosis of myopericarditis is usually difficult and not reliable by physical examination alone. For example in our case and other previous reports, despite the massive pleural effusion and the severe

heart failure, cardiovascular examination revealed no specific findings [2,4]. This phenomenon may be due to the overlapping features of low cardiac output (severe myocarditis) and constrictive cardiomyopathy (tamponade). Therefore, we should consider paramedical evaluation such as chest X-ray, electrocardiography, and echocardiography, even cardiac biopsy, in any case for whom there is a suspicion of cardiac involvement during the course of influenza infection. Takeuchi et al. [5] and Mavrogeni et al. [8] recently demonstrated that T2-weighted magnetic resonance imaging is more reliable than invasive cardiac biopsy and echocardiography in the diagnosis of myocarditis due to the H1N1 virus and also to estimate the severity and activity of the inflammation.

Our study demonstrates that cardiac tamponade resulting from fulminant myopericarditis can occur during the novel H1N1 influenza A infection in young healthy adults without known predisposing factors. Early diagnosis and the intensive care and treatment of such cases can reduce the risk of further cardiac events.

Declaration of interest: The authors report no conflict of interest regarding this work. There was no fund for this study.

References

- [1] US Centers for Disease Control and Prevention. Outbreak of swine-origin influenza A (H1N1) virus infection—Mexico, March–April 2009. *MMWR Morb Mortal Wkly Rep* 2009;58:467–70.
- [2] Koranyi K, Yontz D, Rohrer Z, Leber A, Ramilo O. Pericardial effusion complicating novel influenza A (H1N1) infection in an infant. *Pediatr Infect Dis J* 2010;29:782–3.
- [3] Bratincsák A, El-Said HG, Bradley JS, Shayan K, Grossfeld PD, Cannavino CR. Fulminant myocarditis associated with pandemic H1N1 influenza A virus in children. *J Am Coll Cardiol* 2010;55:928–9.
- [4] Puzelli S, Buonaguro FM, Facchini M, Palmieri A, Calzoletti L, De Marco MA, et al. The Surveillance Group for Pandemic H1N1 2009 Influenza Virus in Italy, and the Campania H1N1 Task Force. Cardiac tamponade and heart failure due to myopericarditis as a presentation of infection with the pandemic H1N1 2009 influenza A virus. *J Clin Microbiol* 2010;48:2298–300.
- [5] Takeuchi I, Imaki R, Inomata T, Soma K, Izumi T. MRI is useful for diagnosis of H1N1 fulminant myocarditis. *Circ J* 2010;74:2758–9.
- [6] Penela D, Regueiro-Cueva A, Ortiz JT, Sitges M. Myocarditis due to pandemic influenza A (H1N1). *Rev Esp Cardiol* 2010;63:1382–9.
- [7] Al-Amoodi M, Rao K, Rao S, Brewer JH, Magalski A, Chhatrwalla AK. Fulminant myocarditis due to H1N1 influenza. *Circ Heart Fail* 2010;3:e7–9.
- [8] Mavrogeni S, Manoussakis MN. Myocarditis as a complication of influenza A (H1N1): evaluation using cardiovascular magnetic resonance imaging. *Hellenic J Cardiol* 2010;51:379–80.
- [9] Mamas MA, Fraser D, Neyses L. Cardiovascular manifestations associated with influenza virus infection. *Int J Cardiol* 2008;130:304–9.